

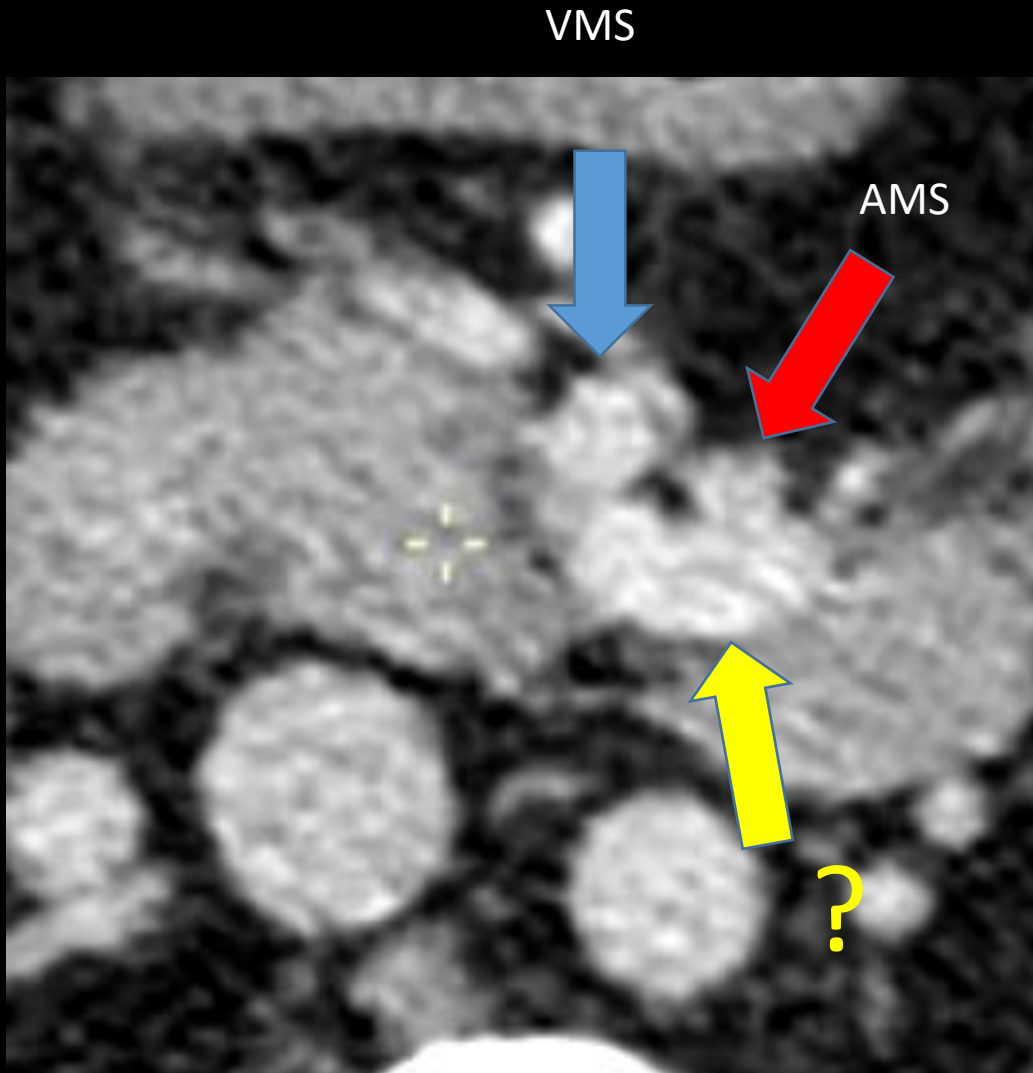
Staff RX 19/02

Puissant Guillaume

Abdomen

1-3

Question Staff



Quelle est la structure indiquée par la flèche jaune:

- 1) Duodénum
- 2) VMI
- 3) Veine jéjunale
- 4) Veine splénique

Cas clinique

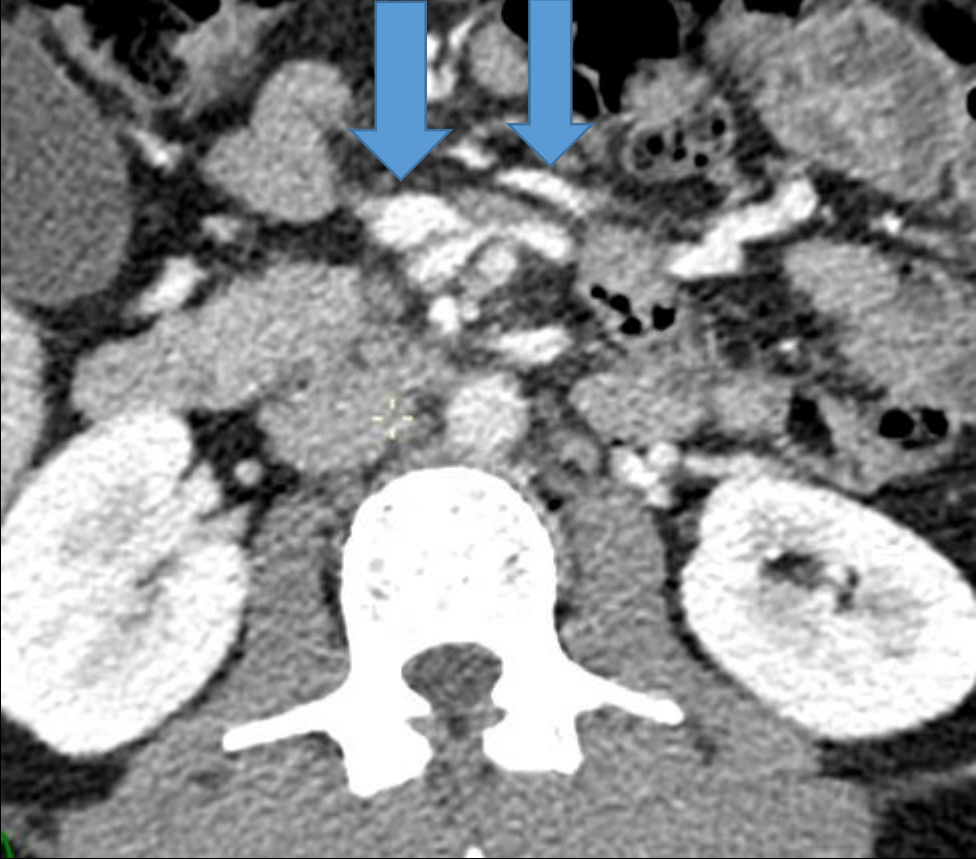
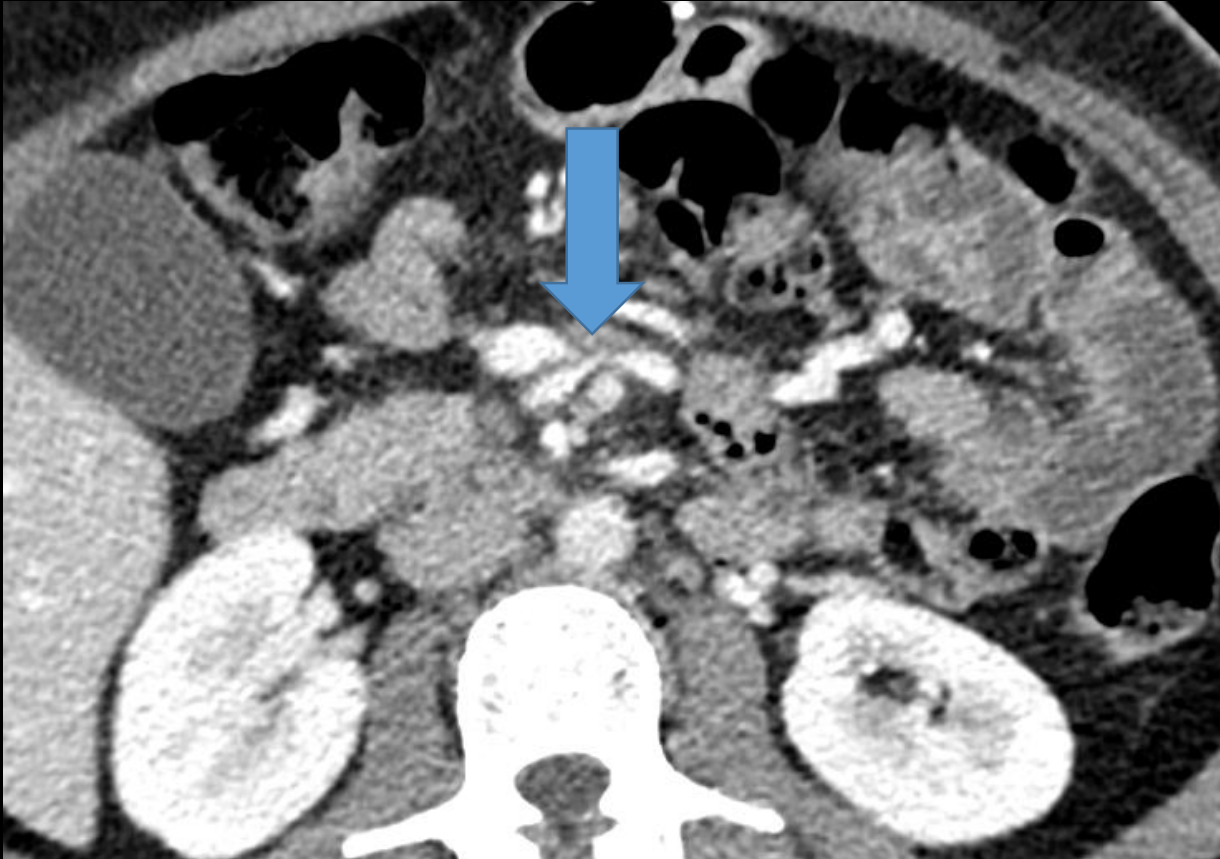- Femme
- 35 ans
- Douleurs en FIG non soulagées par antalgiques
- Antécédent de By-Pass
- Exclure ischémie/hernie interne/autre

CT abdomen - diagnostic ?

- Qu'est ce qui vous interpelle ?

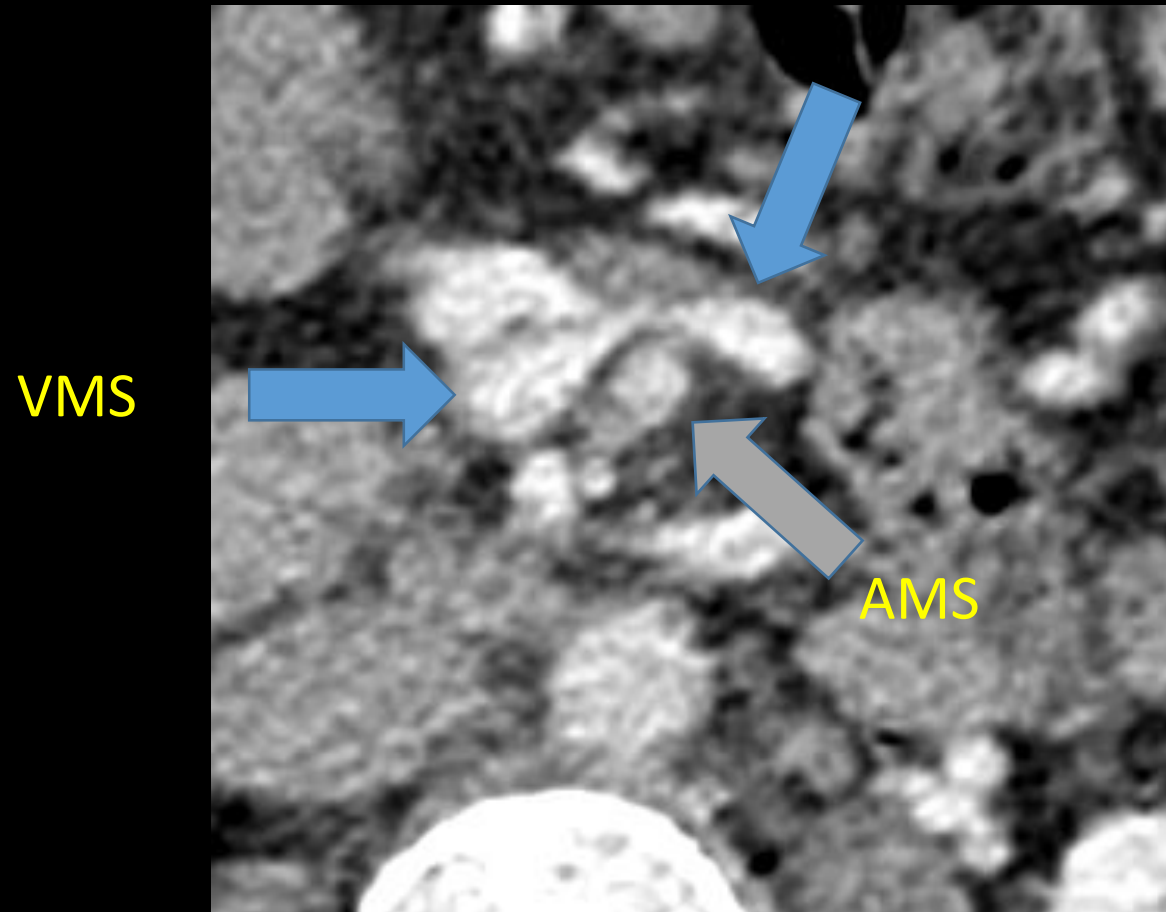
Diagnostic

Qu'est ce qui interpelle ? Deux images



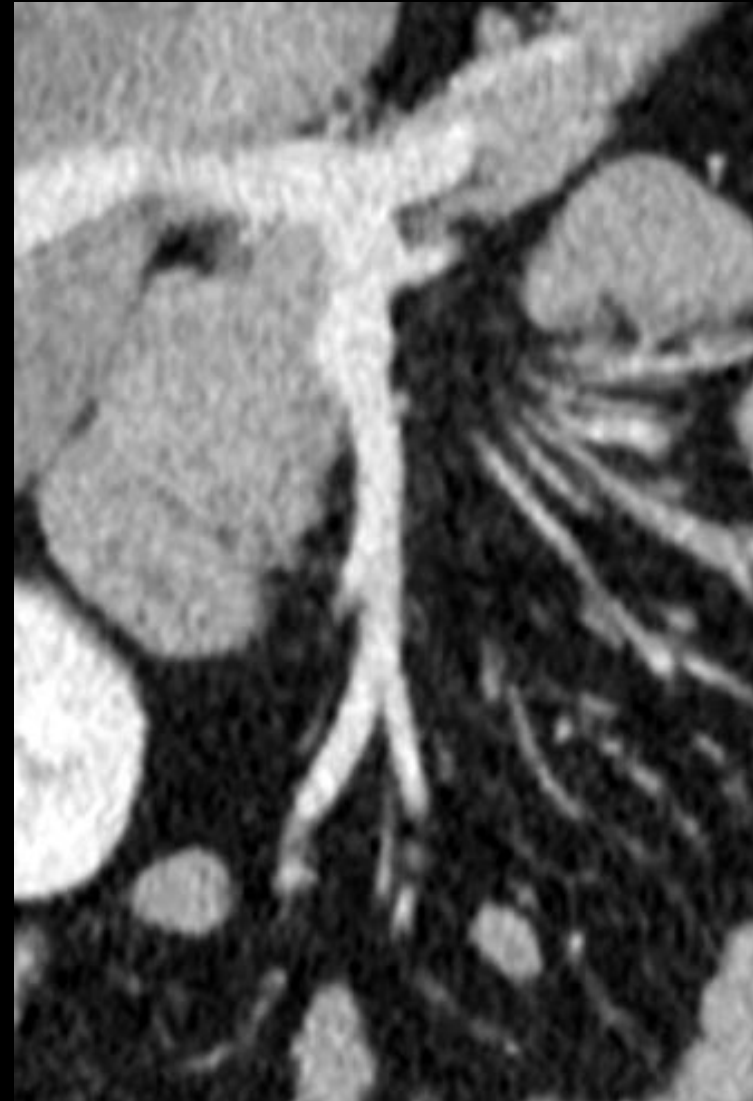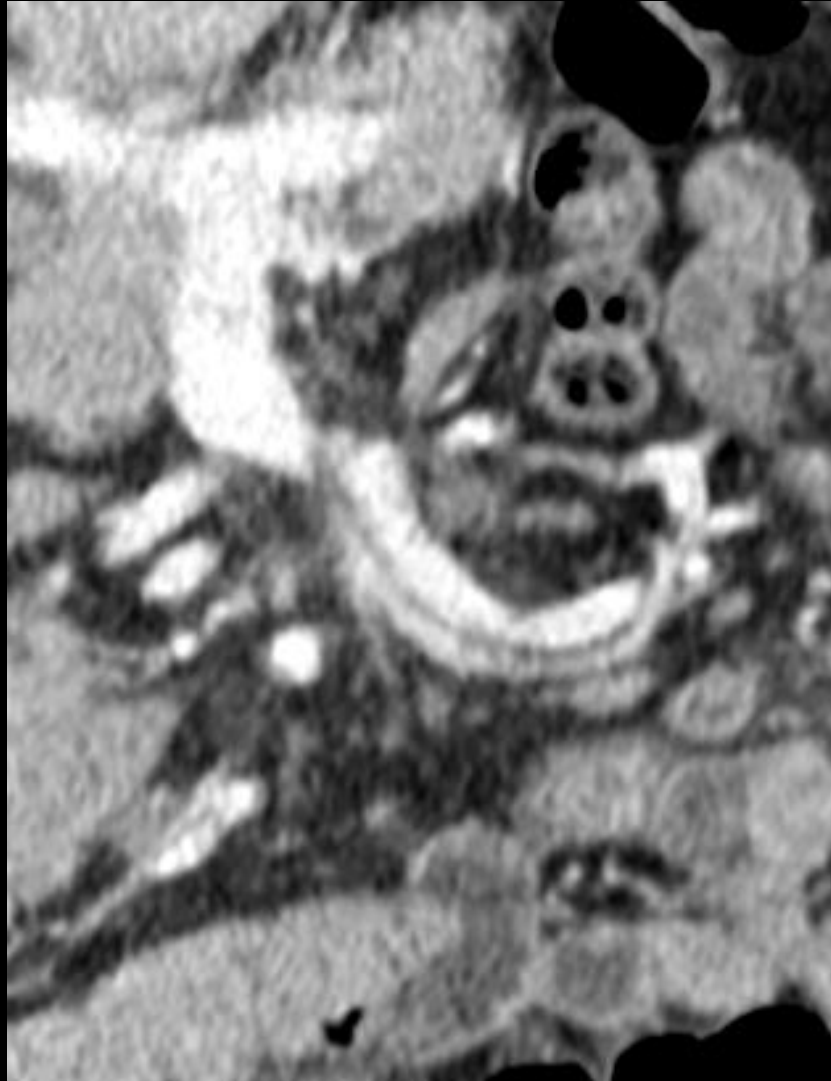Diagnostic

- VMS qui passe à gauche de la LM, en passant devant l'AMS



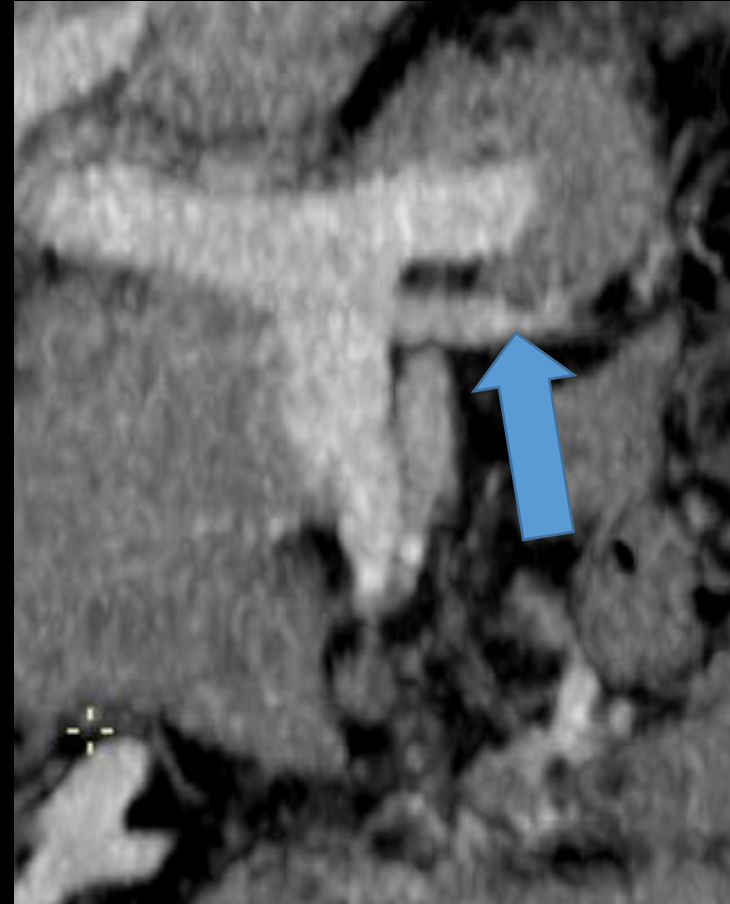
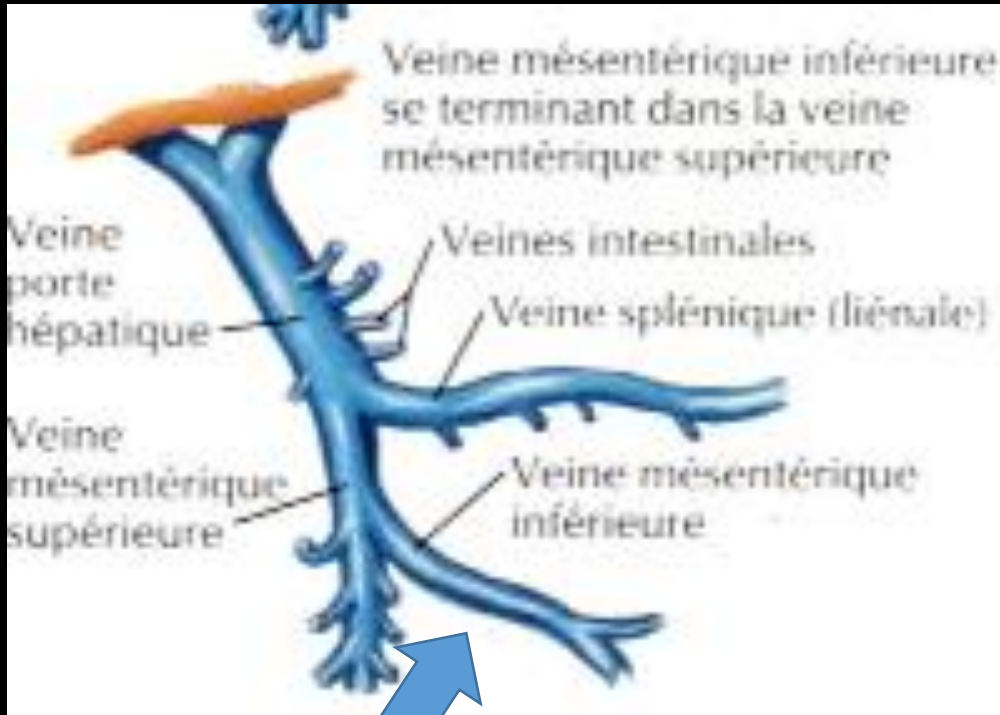
VMS beaking sign
swirl sign

Comparaison avec sujet sain

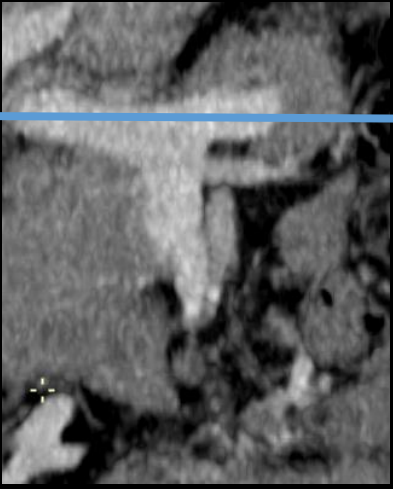

Anatomie

Variante fréquente de l'anatomie porte: VMI qui se jette dan la VMS

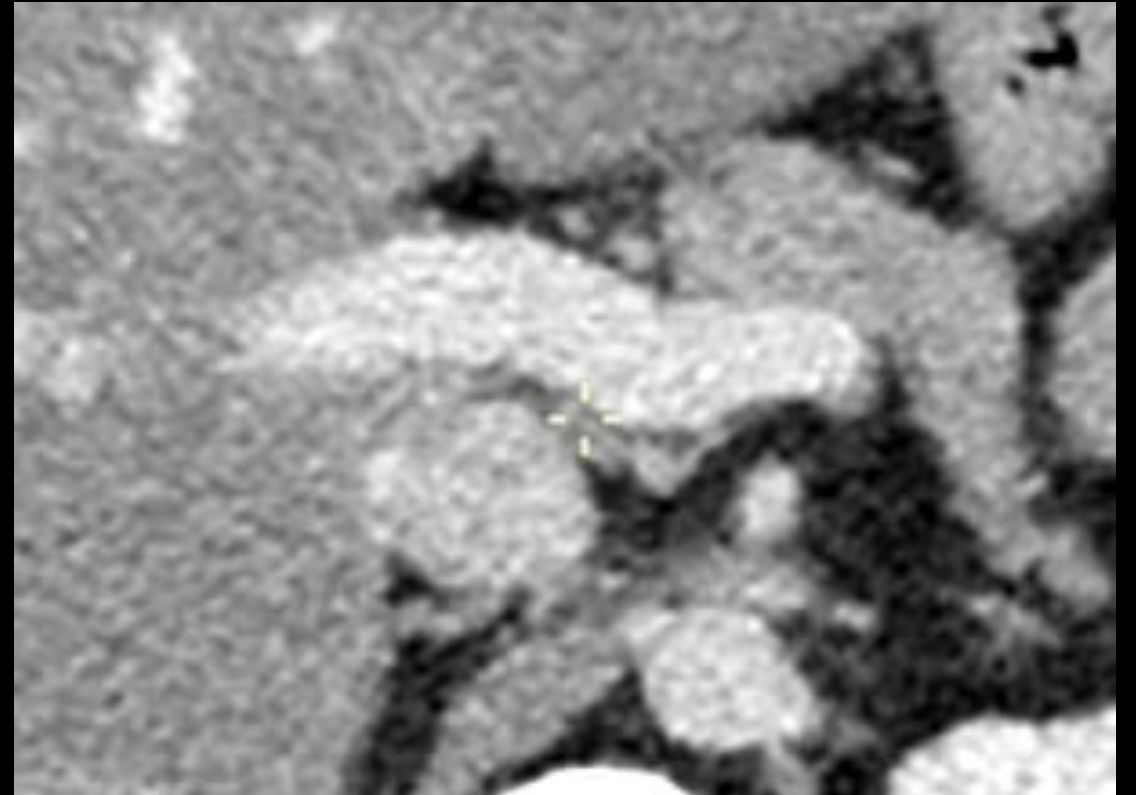
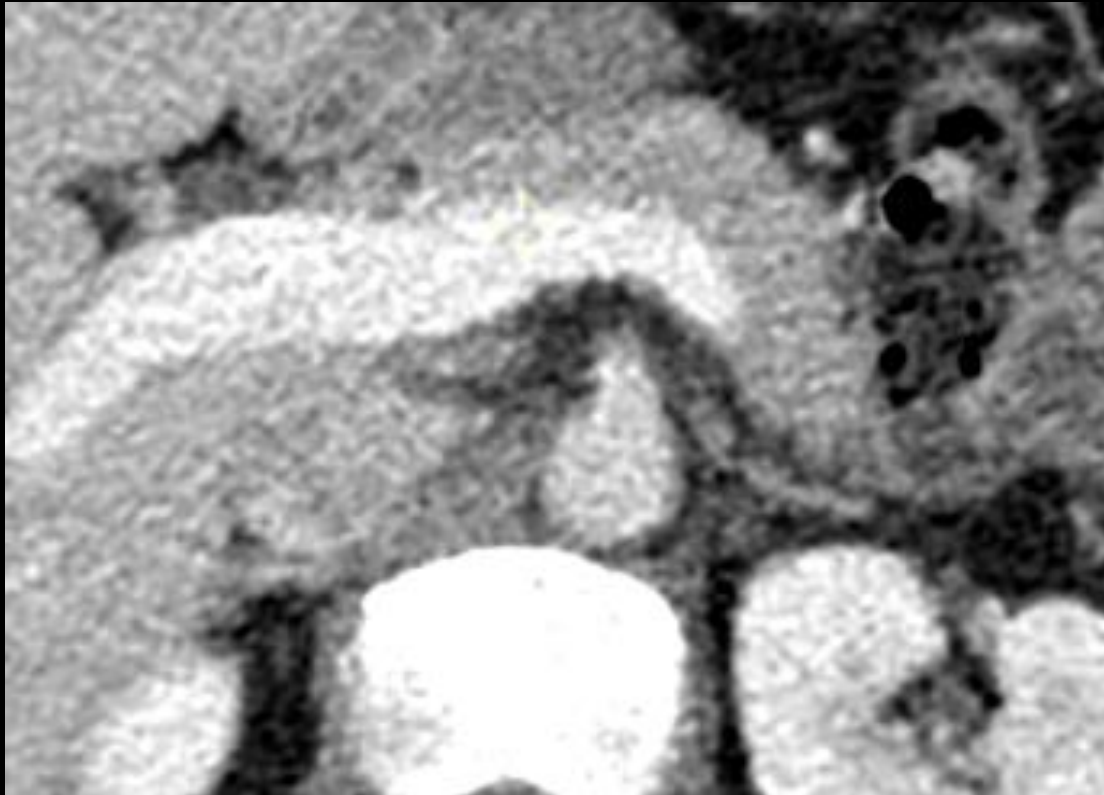


Comparaison

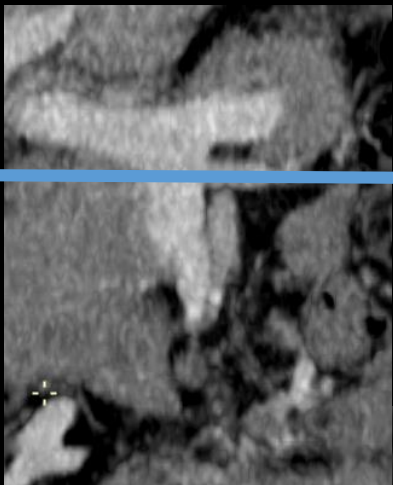


Patient

Patient comparatif

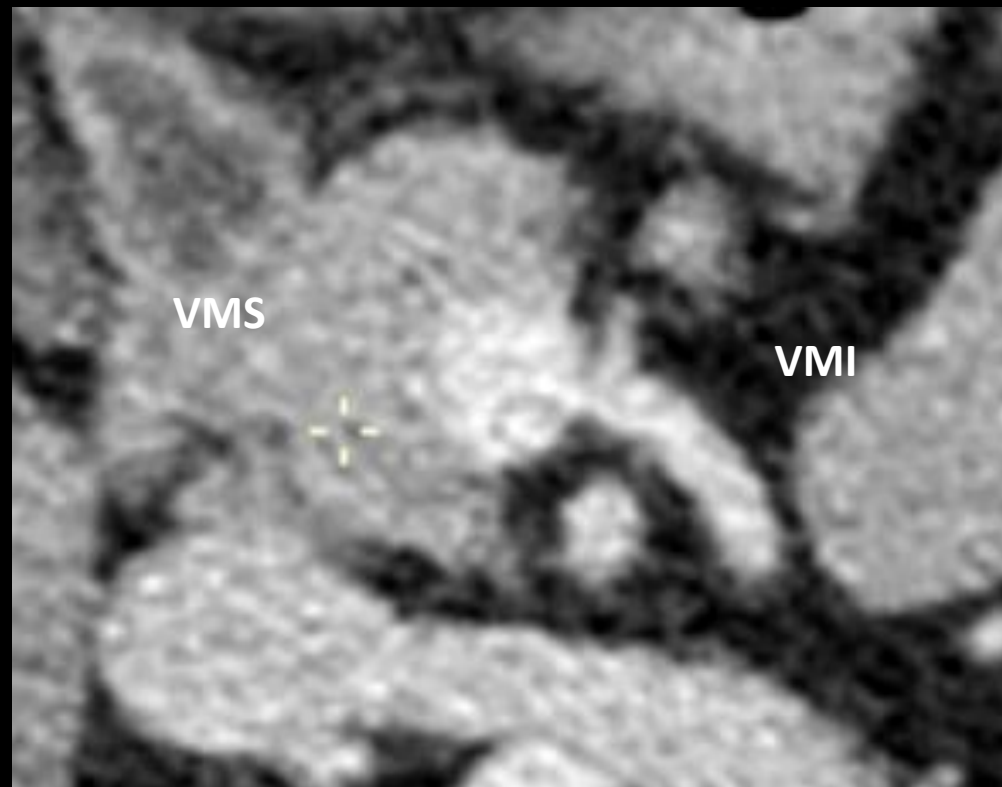
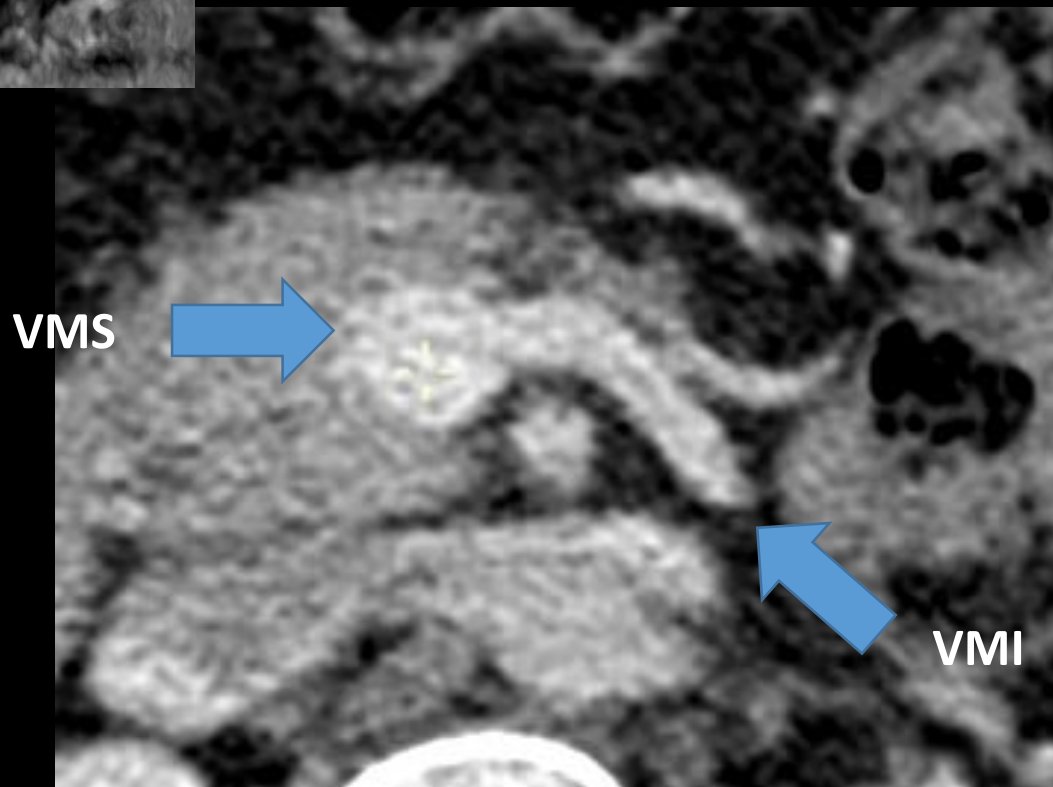


Comparaison

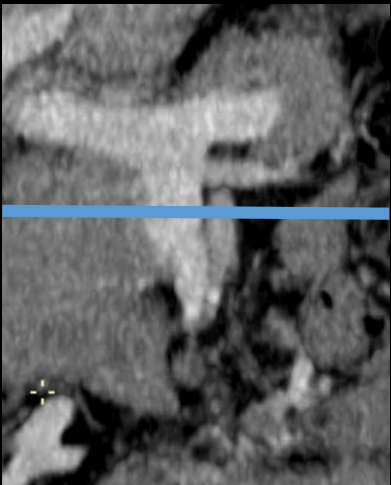

Patient

Patient comparatif

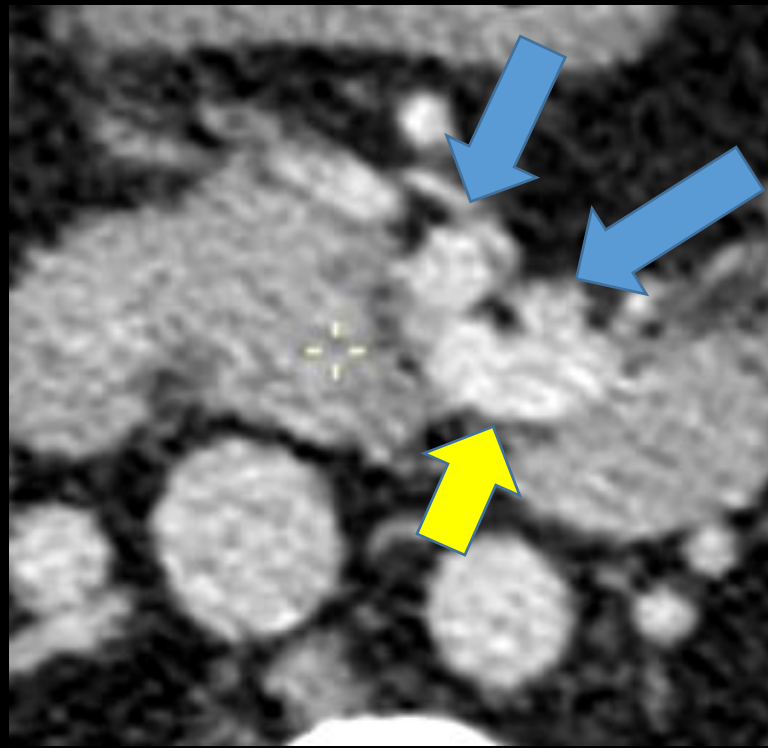
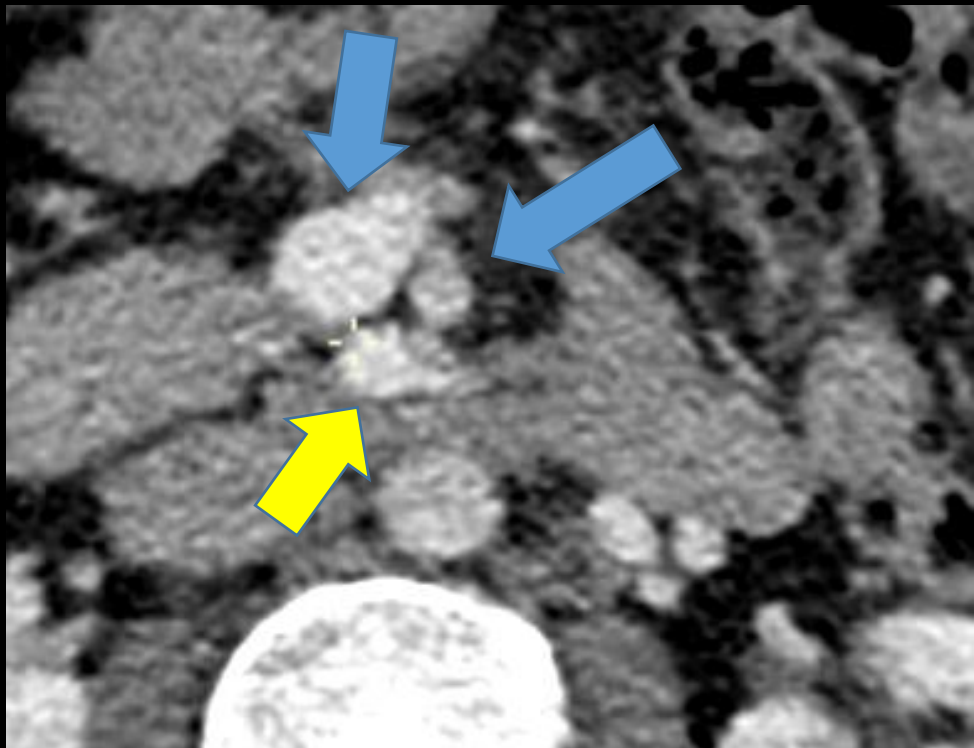


Comparaison

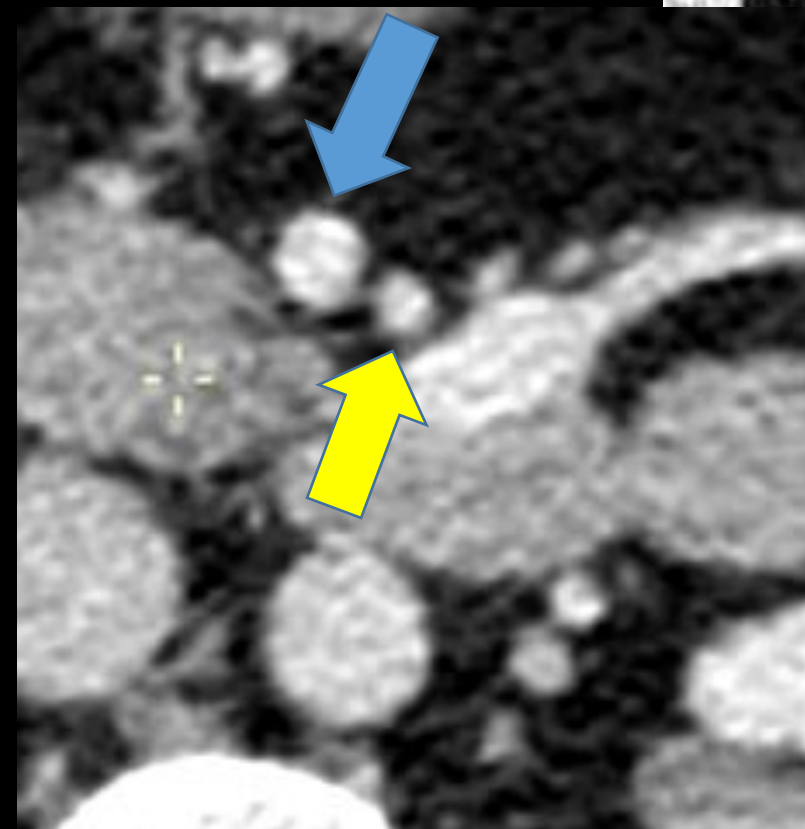
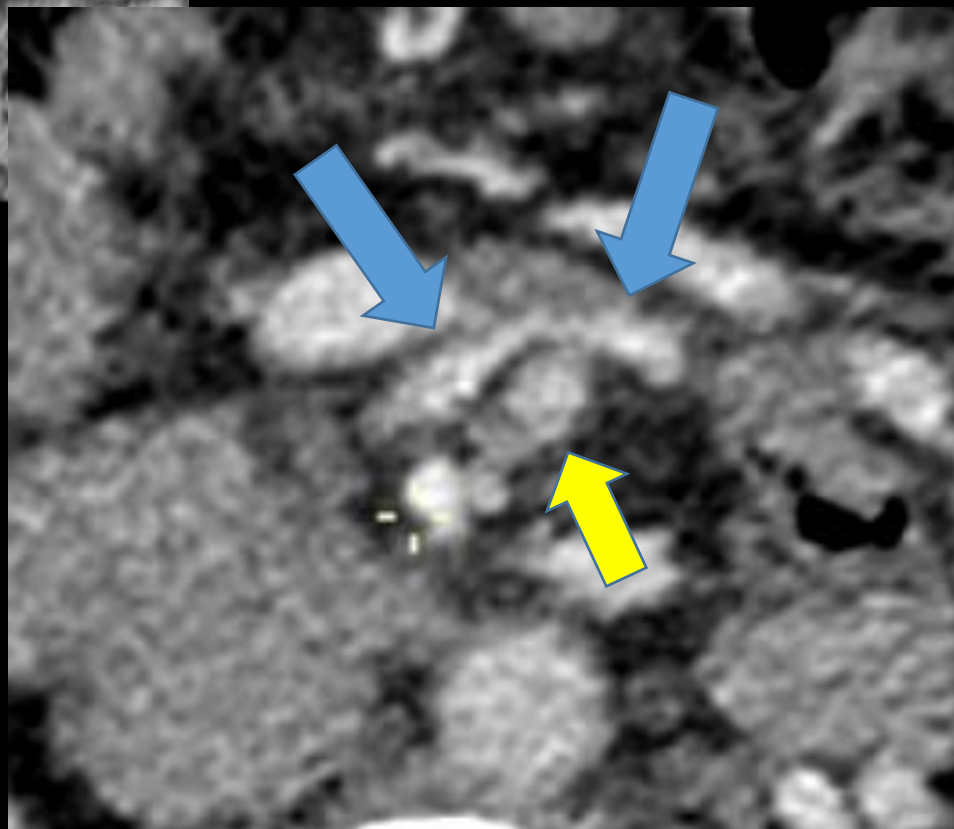
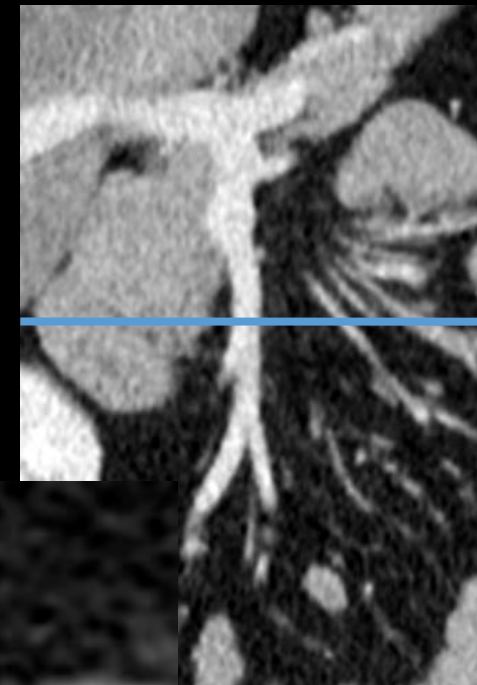
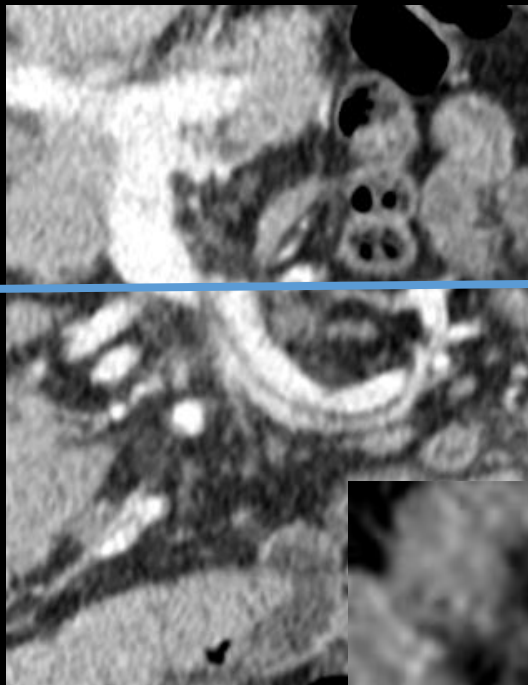


Patient

Patient comparatif

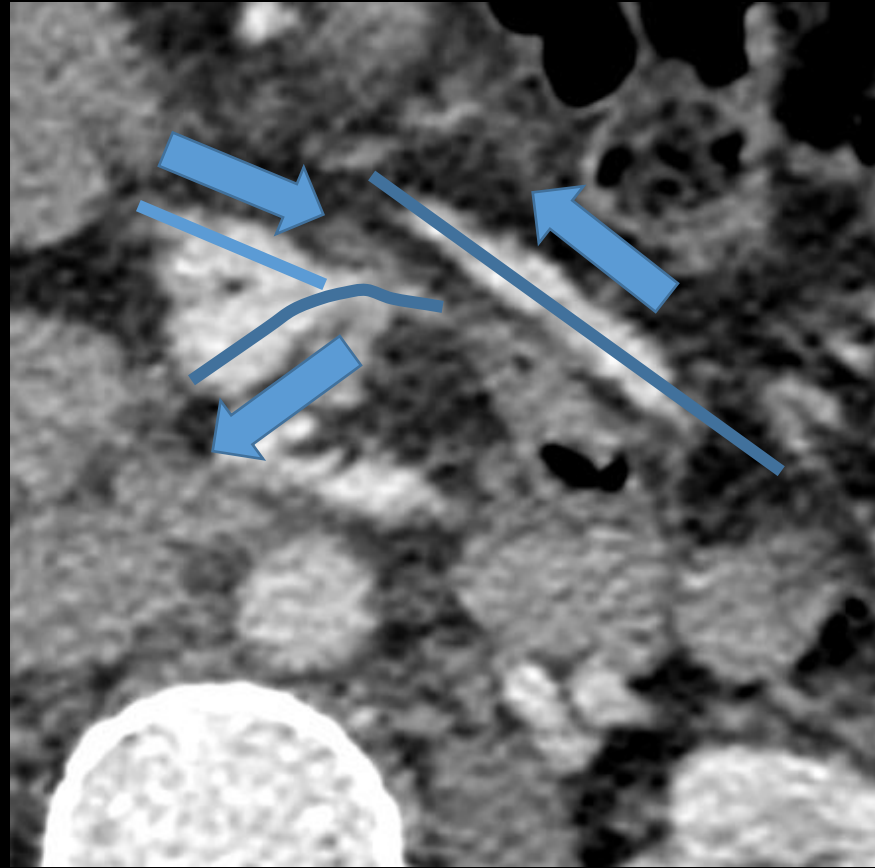
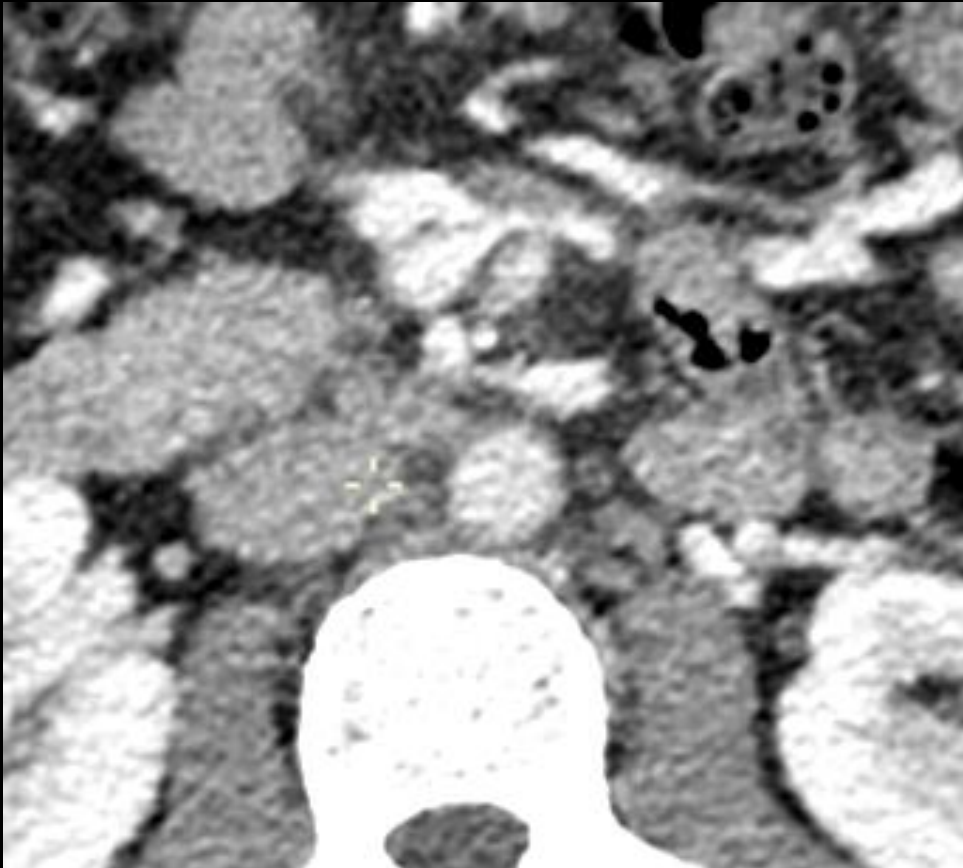


Comparaison



Diagnostic

- Veines iléales traversant la ligne médiane, croisements veineux en X

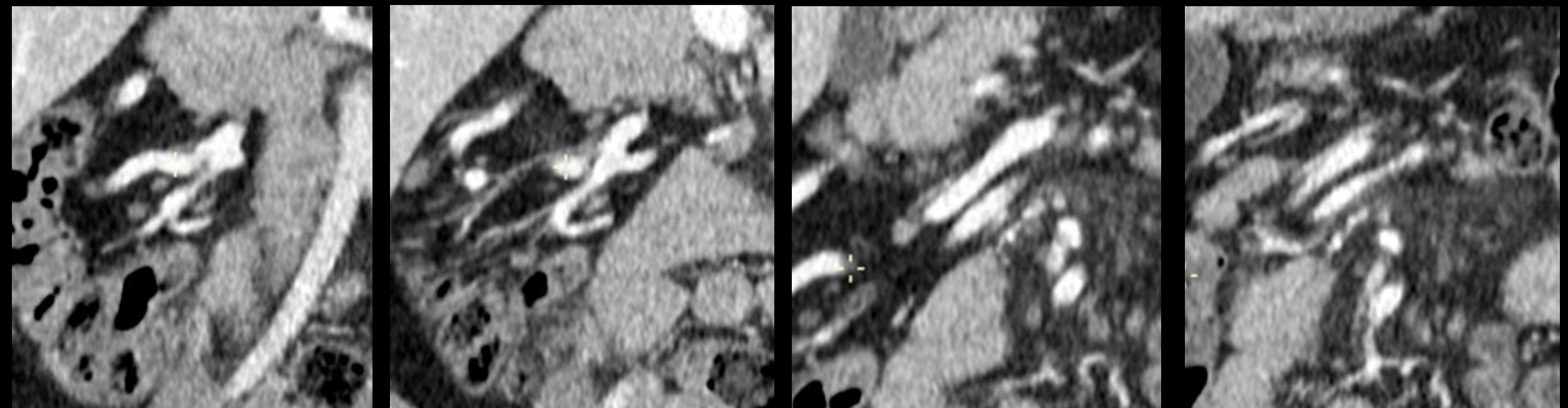


Phase portale
Flux veineux :
périphérie → centre

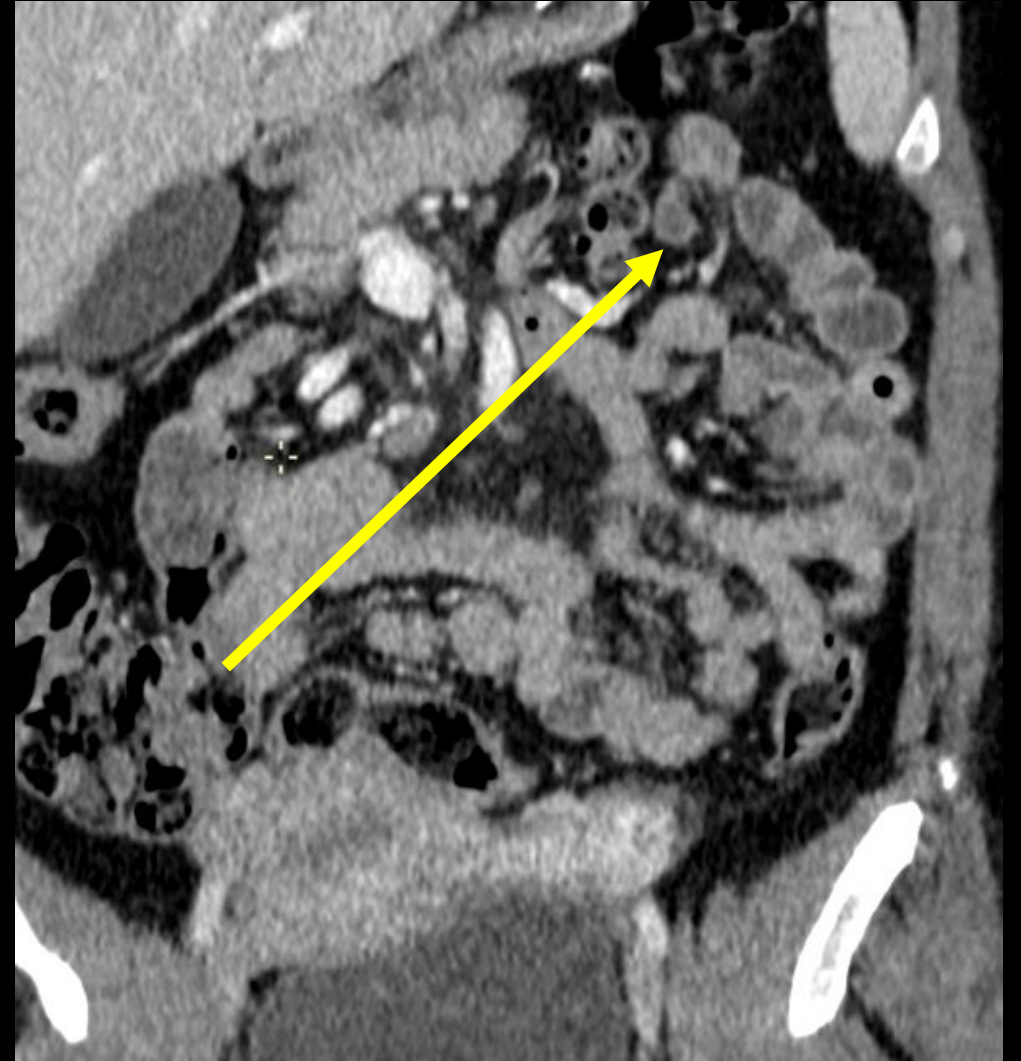Croisements veineux

Diagnostic

- 2) Veines iléales traversant la ligne médiane, croisements veineux en X.

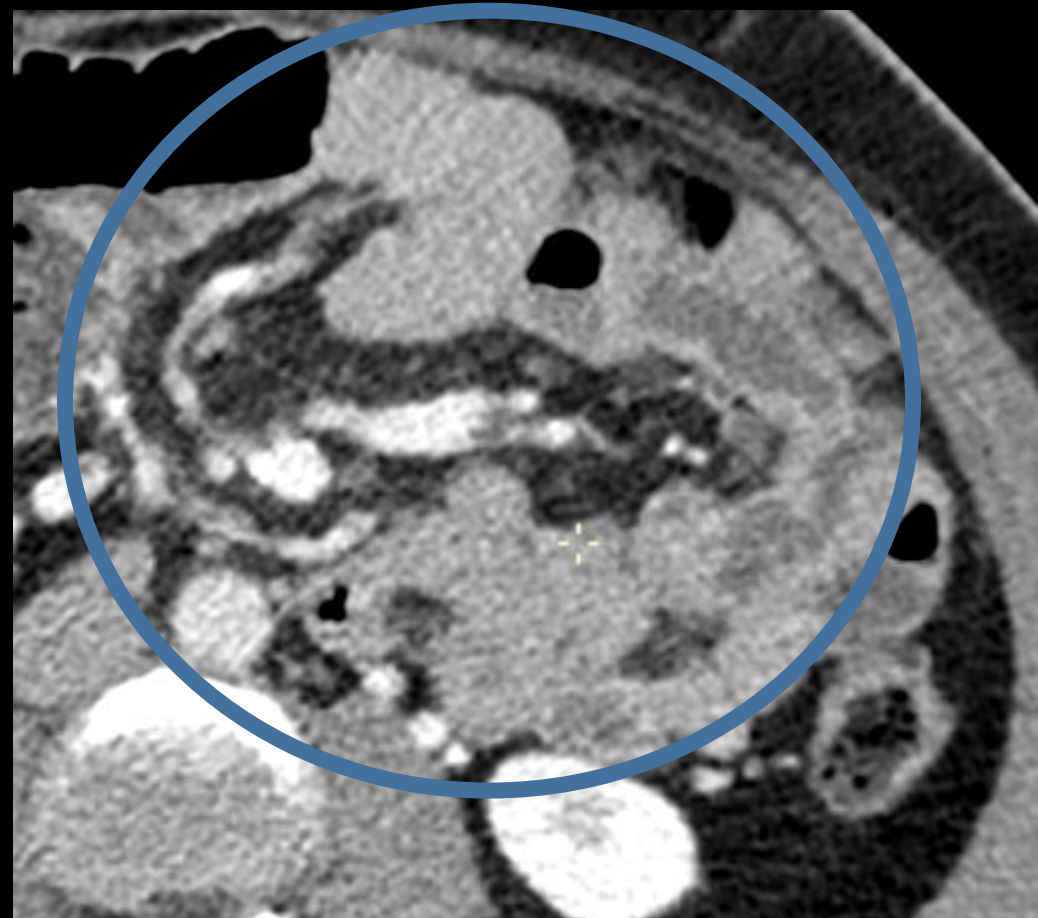
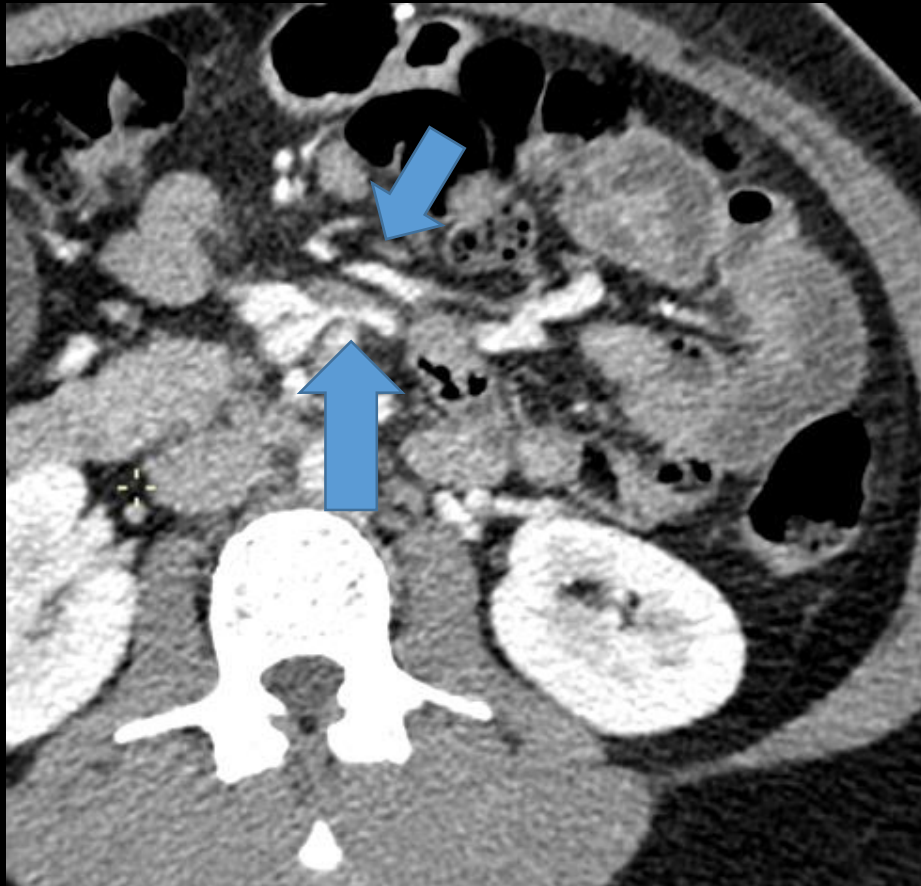


Croisements veineux



Diagnostic

- Hernie interne transmésentérique

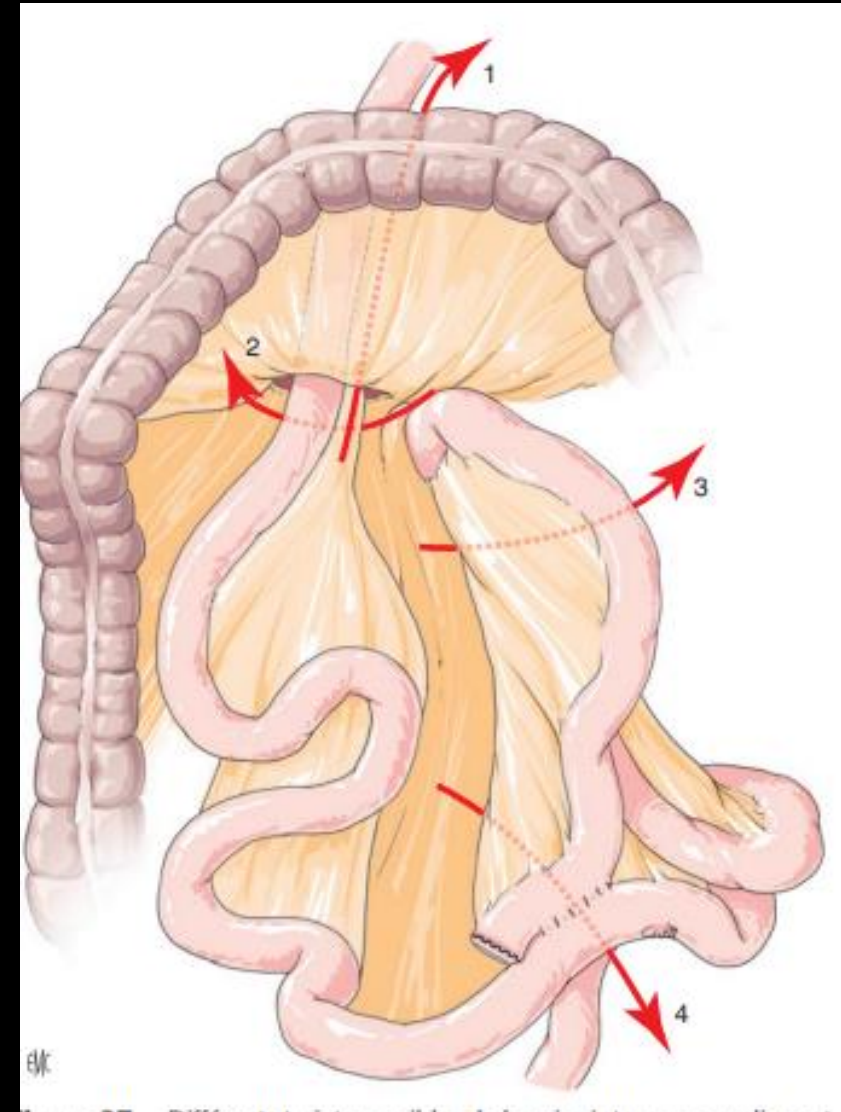


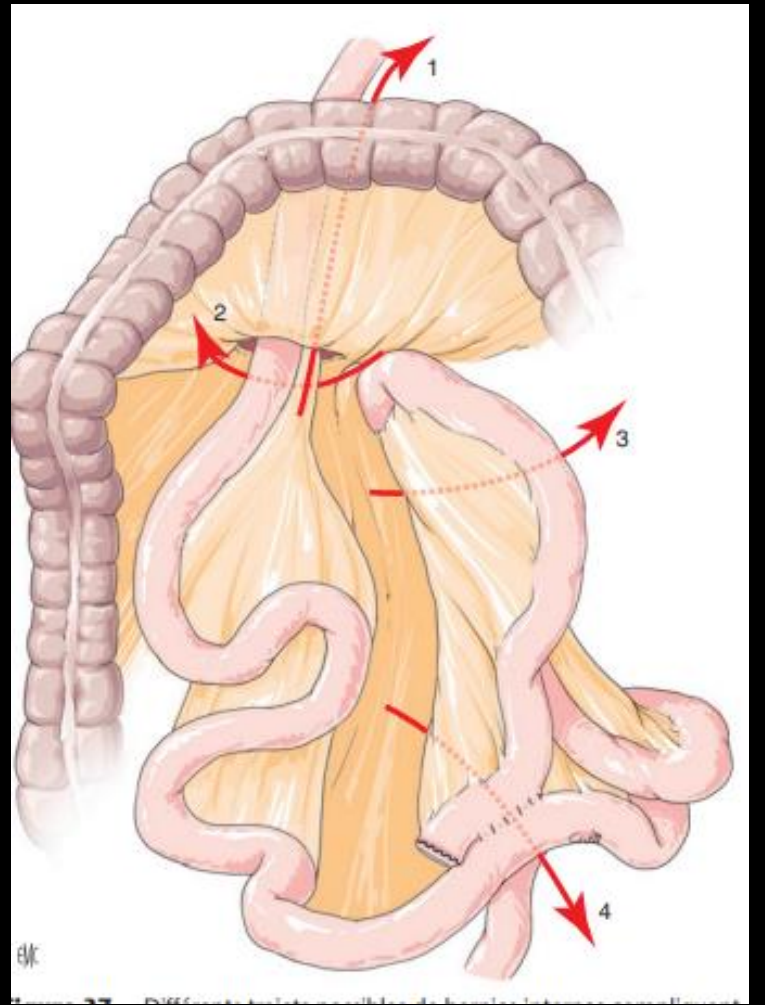
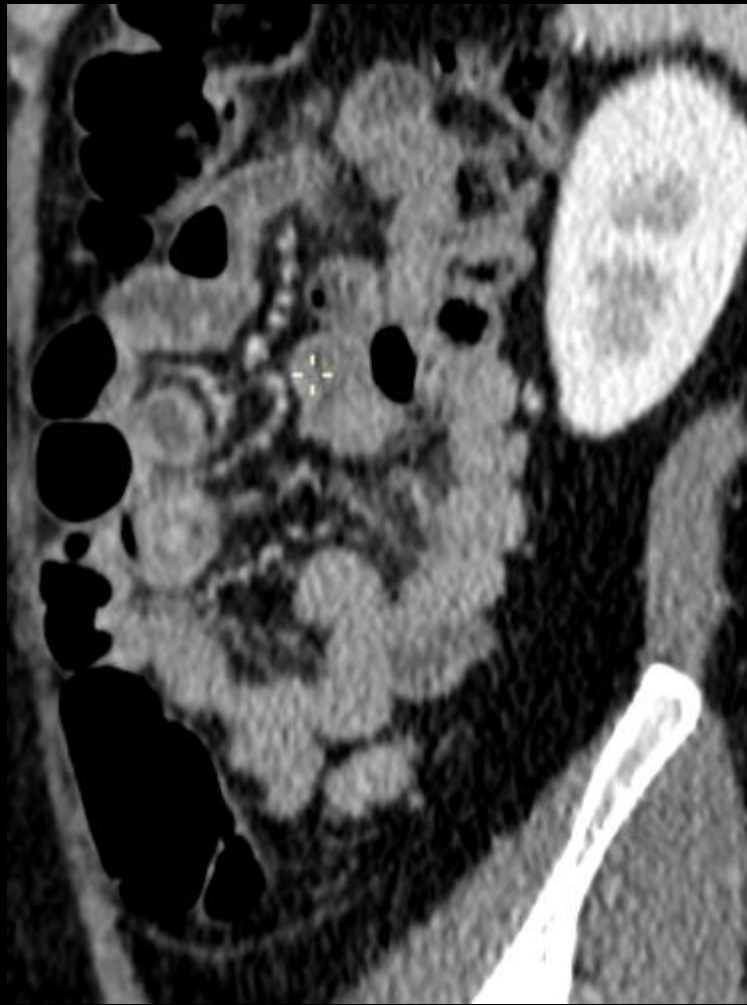
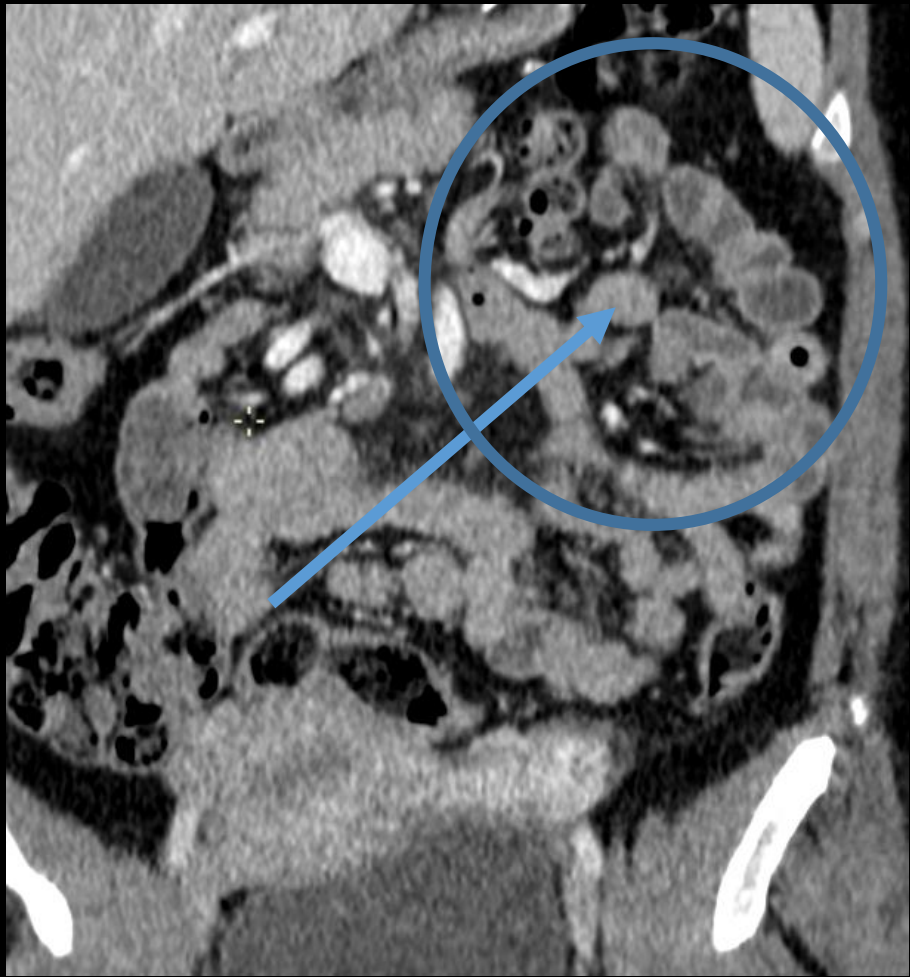
Hernie interne

- Passage de viscères creux au sein d'un orifice péritonéal
- Cause la plus fréquente d'occlusion/douleurs post by-pass (fragilité des mésos)
- Clinique : douleurs abdominales aiguës/chroniques intermittentes

Hernie interne

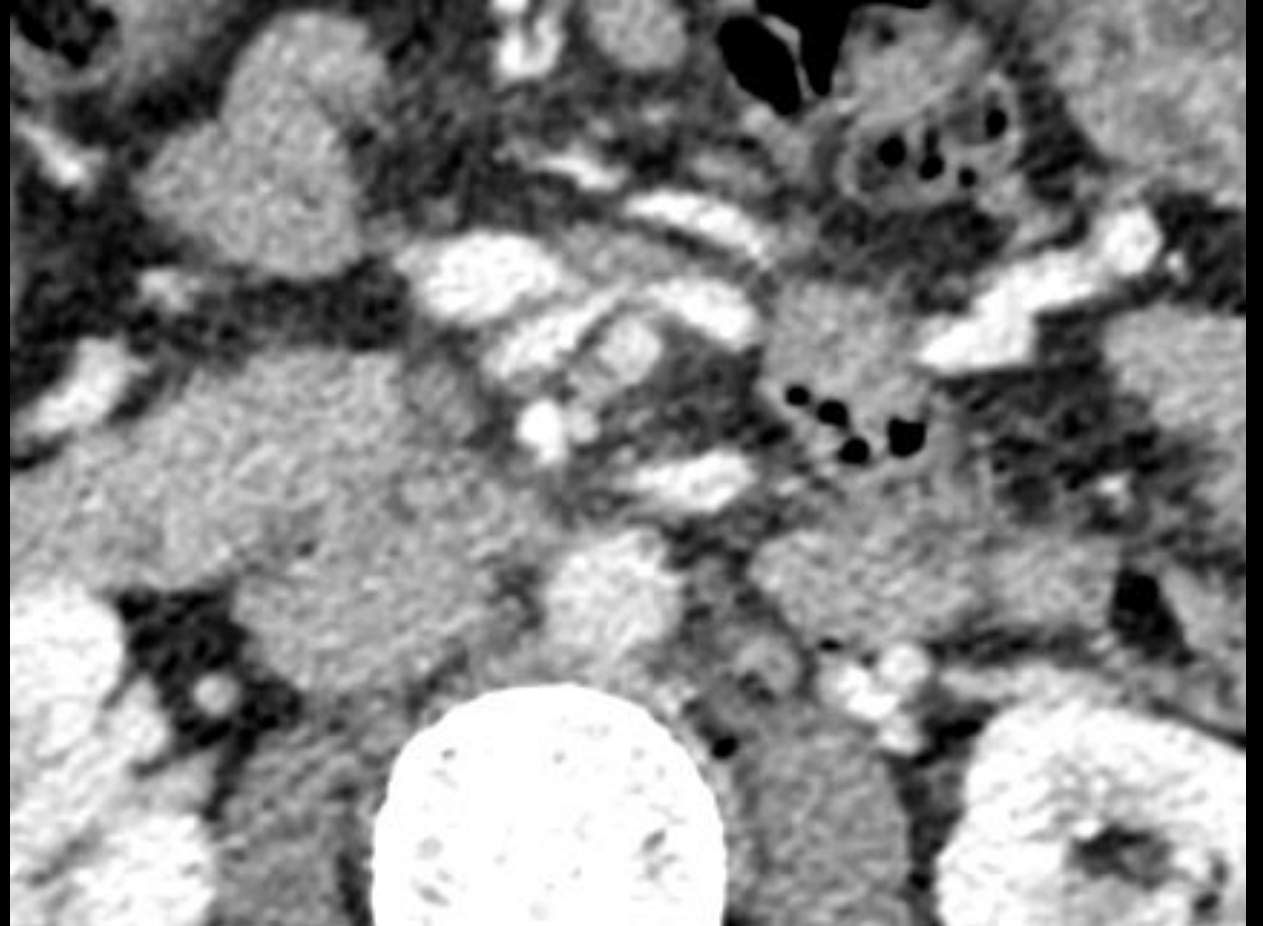

- 4 sites post by-pass
- Transmésocolique (1)
- Espace de Peterson (2)
- **Transmésentérique (3)**
- Hernie de Paroz





Hernie interne : signes au CT

- Swirl sign
- VMS beaking sign

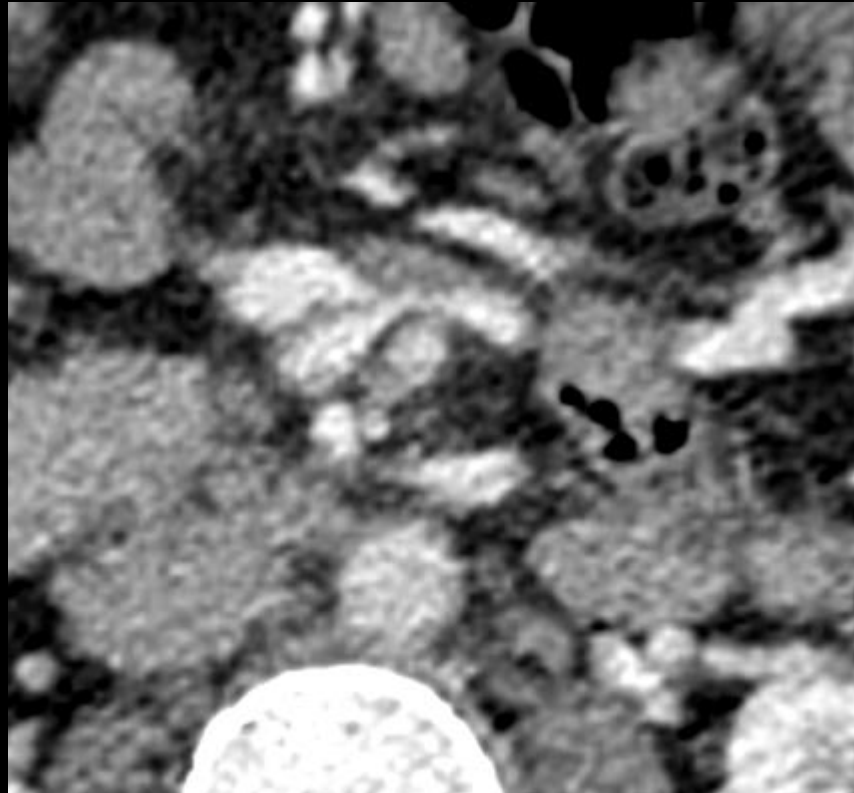


Hernie interne

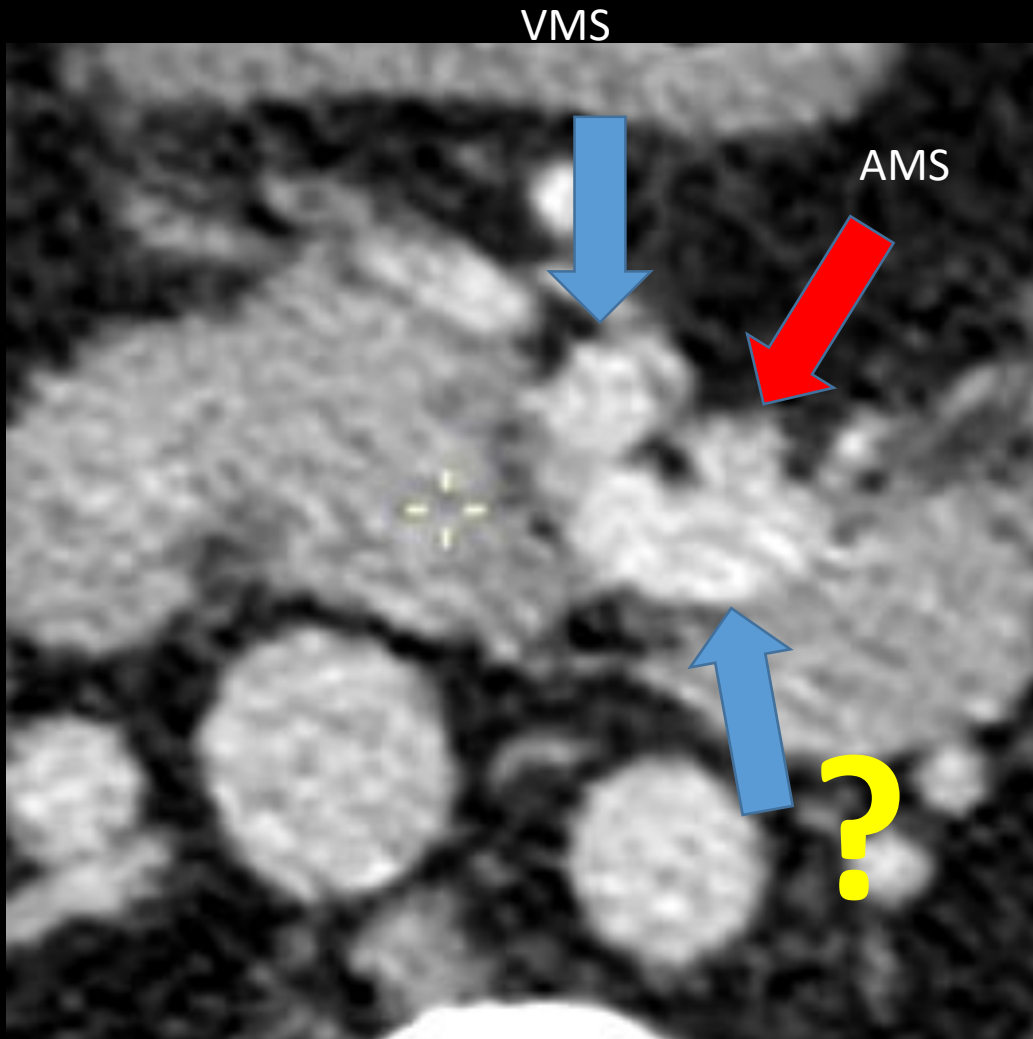
- Hernie interne = hernie sans sac : pas de péritoine pariétal (-/- hernie inguinale)
- Diagnostic complexe en l'absence d'occlusion
- ! Signes indirects : **anses agglutinées + anomalies vasculaires.**

Take home message

- ! En cas de suspicion d'hernie interne après by-pass
- Importance des **signes vasculaires**



Question Staff



A quelle structure correspond la flèche:

- Duodénum
- VMI
- Branche iléale de la VMS
- Veine splénique